

Value of ultrasonography in assessment of acute abdominal pain in male population

Ankit Kumar^{1*}, Mohit Deswal², Arshad Alam Khan², Ashita Jain², B B Sharma³

¹ Radio-Imaging Technology, SGT University, Gurugram, Haryana, India

² Assistant Professor, Faculty of Allied Health Sciences, SGT University, Gurugram, Haryana, India

³ Professor & HOD, Faculty of Medicine & Health Sciences, SGT University, Gurugram, Haryana, India

Abstract

Purpose: The aim of this study is to evaluate the role of ultrasonography in different diagnostic conditions of abdomen.

Methodology: In this prospective study 55 male patients of USG abdomen were included and stat for result was mean and percentage stats used.

Result: out of 80 male patients, out of which 19 (23.75%) patients have fatty liver, 11 (13.75%) patients have right renal calculus, 8 (10%) patient have left renal calculus, 3(3.75%) patient have B/L renal calculus, 4 (5%) patients have acute pancreatitis, 3 (3.75%) patients have acute appendicitis, 2 (2.5%) patients have liver abscess, 6 (7.5%) patients have cyst, 6 (7.5%) patients have ascites, 17 (21.25%) patients have cholelithiasis and 1 (1.25%) patient have normal. Sonography play key role in to visualized gross primary investigation in abdomen.

Conclusion: The study concludes uses of USG should be perform as a primary investigation for all patients. This study has shown a relatively high sensitivity, specificity and diagnostic accuracy of USG in cases of acute abdomen in a careful hand. USG is currently considered the preferred initial imaging technique for patients who are clinically suspected of having fatty liver, renal calculus, acute pancreatitis, acute appendicitis, ascites, cyst, liver abscess and cholelithiasis etc.

Keywords: USG, B/L, appendicitis, cholelithiasis, fatty liver, cyst

Introduction

Ultrasound is the equipment used to diagnose the disease. An ultrasound scan could be a medical test that uses high-frequency sound waves to capture real time images of the organ. Different sorts of transducer or probe are used to supply the USG image. Abdominal sonography could be a sort of USG study use highfrequency transducer ranging from 3.5-10MHz). USG study used for the male and feminine patients to find out the pathologies. Ultrasound abdomen is one of the tests that's commonly employed in symptoms of abdominal pain. It is especially useful for soft tissue, solid organ, and fluid-filled anatomy ^[1].

Abdominal Anatomy: Ultrasound imaging of the abdomen uses sound waves to form the image of structure within the abdomen. It evaluates the kidney, liver, gall bladder, bill duct, pancreas, spleen, and aorta. The abdomen is divided into 4 quadrants or 9 regions by two sagittal plans and two transverse plans. The umbilicus server at the center of the nine regions each region and its associated organ well ^[2].

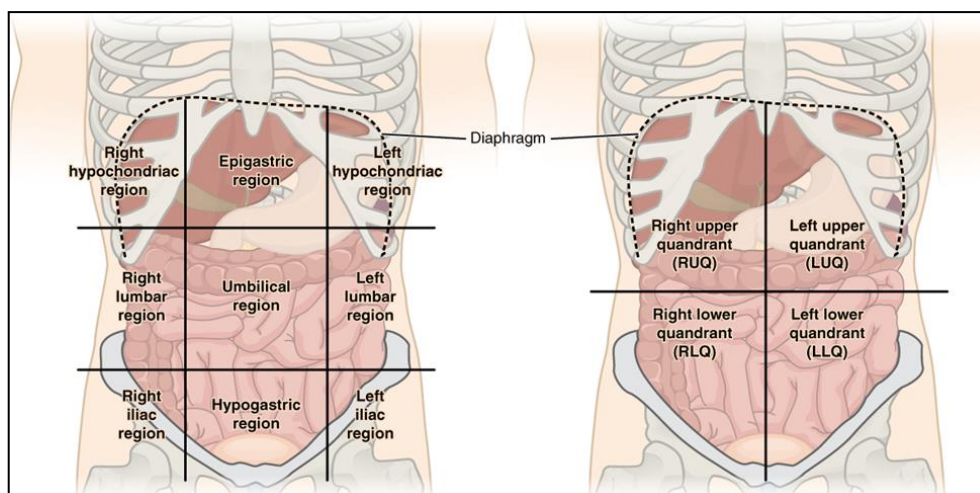


Fig 1: abdominal anatomy by quadrants and regions 1.2 symptoms/indication and clinical condition

The indication of abdominal USG is abdomen pain, ascites (Fluid-filled in the abdominal cavity), aneurysm (A ballooning and weakened area in an artery), unexplained fever, trauma (internal bleeding). Abdominal pain is the most common symptom. Abdominal USG includes some pathologies like the 2 differential diagnose of acute abdominal pain including appendicitis, ulceration urinary stones inflammatory bowel disease, biliary colic cholecystic, and pancreatitis ^[3].

Causes of abdominal pain: Acute abdomen may be a condition that demands urgent attention and treatment. The acute abdomen may be common causes of abdominal pain or appendicitis, gastroesophageal reflux disease (GERD), pancreatitis, gallbladder disease, diverticulitis, and tiny bowel obstruction, an infection, inflammation, vascular occlusion, or obstruction. The patient will usually present with sudden onset of abdominal pain with associated nausea or vomiting. Most patients with acute abdomen appear ill ^[4].

History: The Radiologist or technologist should obtain a complete history of the patient. This could be generally the corners of an accurate diagnose. A very detailed history taken from the patient about any previous diagnostic, pathology, or other reports must be present to the patient so that comparison easily is done. This could be providing important information ^[5].

Role of ultrasound in the abdomen: The abdominal cavity consists of many organ-like kidneys, gallbladder, pancreas, liver, intestine etc. When the patients come to the hospital with abdomen pain. Diagnose of the patient with abdomen pain finds by imaging technology like ultrasound, computerized tomography, Magnetic resonance imaging, etc. Abdominal ultrasound the Diagnose of the cavum with abdomen symptoms. Ultrasound is additionally useful for the Diagnose of solid organ conditions including acute cholangitis, acute cholecystitis, acute pancreatitis, or bowel disease. CT is that the 1st line procedure suggests to the patient but CT is an invasive procedure or high-cost price but USG is a non-invasive procedure or cheap cost so that we preferred USG for the suspected patient. during this case, abdominal ultrasound is that the 1st line procedure to judge its utility and limitation in determining the Diagnose of patients presenting with abdominal symptoms ^[6].

USG role in kidney: Renal calculi are a common reason for hematuria likewise as abdominal pain. High speed & portability has made USG the primary diagnostic in many clinical conditions. The accuracy of USG is very obsessed with the talents of the operators. Advancement of USG equipment in recent year have improved the standard of image, especially the spatial resolution ^[6].

USG role in Gallbladder: Cholelithiasis is the most common condition of GB. GB which results in liver abscess may be a rare complication of acute, chronic, or empyema gallbladder. USG scan is the foremost important diagnostic tool to Diagnose during this rear complication ^[7].

USG role in pancreas: USG of the pancreas is challenging, its retroperitoneal location with overlying structure and comparatively small size. the standard thereby the clinical uses of the pancreatic USG imaging has rapidly advanced together with the technological progress. The sensitivity and specificity of Trans abdominal USG within the Diagnose of pancreatic diseases. the flexibility to the difference between acute and chronic inflammation and premalignant or malignant ^[8].

USG role in acute appendix: USG is a crucial clinical tool to diagnose appendicitis. Acute appendicitis is the most typical emergency presentation requiring surgical intervention in both adults and kids. the simplest imaging modality or combination of modalities to accurately and cost-effectively diagnose the condition. Sonographic criteria or techniques that improve accuracy and assist Diagnose would be of particular benefit in appendicitis ^[9].

Precaution: Ultrasound has not a harmful effect like X-ray and CT because x-rays are ionizing radiation but ultrasound has non-ionizing. Ultrasound has an invasive procedure. They need only acoustic wave which isn't harmful its mean ultrasound has not precautioned.

Justification: Ultrasonography is preferred as the best modality for the examination of the abdomen because unlike X-ray and CT that uses ionizing radiation US uses non-ionizing radiation that is safer and provides real-time images.

Aim

Value of ultrasonography in assessment of acute abdominal pain in male population.

Materials and Methods

A quantitative prospective study was performed to assess the role of ultrasonography in abdominal pain in male patients who undergoes abdominal ultrasonography in the radiology department of SGT Hospital and Research Institute, Gurugram. Those male Patients who are undergoing abdominal ultrasonography in the radiology department of SGT Hospital and Research Institute with advised abdominal pain are included in this study. 80 male patients were selected according to the inclusion criteria of this study. Patients will be signing a consent

before the investigation. History was taken from patients prior to investigation. Abdominal ultrasound was performed. This study was carried out between 1st October 2019 to 1st April 2020.

Selection Criteria: In this study following patients under inclusion and exclusion criteria, Data collected after completion of scan and reporting. Male patients with findings under ultrasonography were included in this study, 70 patients with acute abdominal pain, 10 patients traumatic, All IPD and OPD male patient, Age (15-70 years) were taken under inclusion criteria. Post-operative patients, female patient were taken under as exclusion criteria.

Data Analysis: The purpose of data analysis is to categorize, organize, manipulate, and summarize the data that have been collected. The current study used a quantitative design. In this context, quantitative data refer to numbers that are collected and then interpreted using statistics. Numerical data are described in a meaningful manner thereby enabling any researcher to understand interrelationships that exist. Data analysis aims to describe statistical analysis results but does not comment on them. In this study, an analysis was done on the basis of the Mode frequency of findings.

Result

A study was conducted in the department of radiology at SGT hospital to Assessment of USG in acute abdomen pain. Total of 80 patient's data used in this study who complain of acute abdominal pain during the period of study. The result of the scan collected and master chart is prepared. We found that 21.25% patients have acute abdominal pain was due to cholelithiasis, 13.75% patients have right renal calculus, 10% patients have left renal calculus, 3.75% patients have acute appendicitis, 5% patients have acute pancreatitis, 23.75% patients have fatty liver, 2.5% patients have a liver abscess, 7.5% patients have ascites, 7.5% patients have B/L renal calculus, 3.75% patients have cyst and 1.25% patients have normal. In rest 98.75% of patients' ultrasound help to diagnose the problem of acute pain.

Patients were categorized to the analysis of the result of the study in two age groups which were 15- 40years and 40-60 years. Only these two groups were made because of all patients age within this age range.

In the age of group 15-40years, there were a total of 43 male patients. Four most common assessments in this group were fatty liver in 27.90% patients, left renal calculus 16.27%, right renal calculus 18.60 % and cholelithiasis 16.27% patients, rest of the patients were diagnosed with several other findings like B/L renal calculus 2.32%, pancreatitis 2.32%, cyst 6.97%, ascites 4.65%, liver abscess 0% and appendicitis 4.65%, etc.

And In the age group 40-70years, there were a total of 37 male patients. Two most common assessments in this group were Cholelithiasis in 27.02%, fatty liver 18.91% rest of the patients were diagnosed with several other findings like B/L renal calculus 5.40%, pancreatitis 8.10%, cyst 8.10%, ascites 10.81%, appendicitis 2.70% and liver abscess 5.40% etc. Results came out after this study was as follows as shown in table 5.1, 5.2 & 5.3.

Table 1: Shows the analysis of results of USG scan of patients having acute abdominal pain and age range 15-70 years.

Age Group 15-70 Years			
Male	Female	Total	Diagnose
17	0	17	Cholelithiasis
11	0	11	Right Renal Calculus
8	0	8	Left Renal Calculus
3	0	3	Acute Appendicitis
4	0	4	Acute pancreatitis
19	0	19	Fatty liver
1	0	1	Normal Scan
2	0	2	Liver abscess
6	0	6	Ascites
6	0	6	Cyst
3	0	3	B/L Renal Calculus

Table 2: Shows the analysis of results of USG scan of patients having acute abdominal pain and age range 15-40 years.

Age group 15-40 years				
Male	Female	Total	Diagnose	Percentage %
7	0	7	Cholelithiasis	16.27%
8	0	8	Right Renal Calculus	18.60%
7	0	7	Left Renal Calculus	16.27%
2	0	2	Acute Appendicitis	4.65%
1	0	1	Acute Pancreatitis	2.32%
12	0	12	Fatty Liver	27.90%
0	0	0	Normal Scan	0%
0	0	0	Liver Abscess	0%

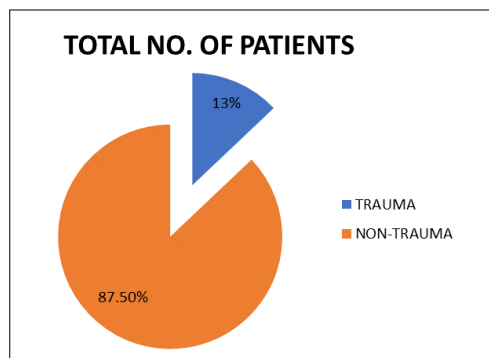
2	0	2	Ascites	4.65%
3	0	3	Cyst	6.97%
1	0	1	B/L Renal Calculus	2.32%

Table 3: Shows the analysis of results of USG scan of patients having acute abdominal pain and age range 40-60years.

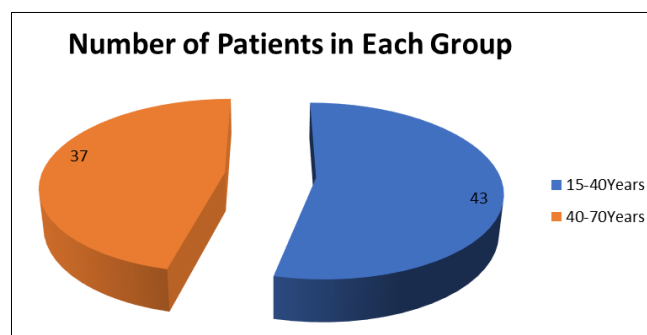
Age group 40-70 years			Diagnose	Percentage%
Male	Female	Total		
10	0	10	Cholelithiasis	27.02%
3	0	3	Right Renal Calculus	8.10%
1	0	1	Left Renal Calculus	2.70%
1	0	1	Acute Appendicitis	2.70%
3	0	3	Acute Pancreatitis	8.10%
7	0	7	Fatty Liver	18.91%
1	0	1	Normal Scan	2.70%
2	0	2	Liver Abscess	5.40%
4	0	4	Ascites	10.18%
3	0	3	Cyst	8.10%
2	0	2	B/L Renal Calculus	5.40%

Table 4: shows the analysis of results of USG scan of patients having acute abdominal pain.

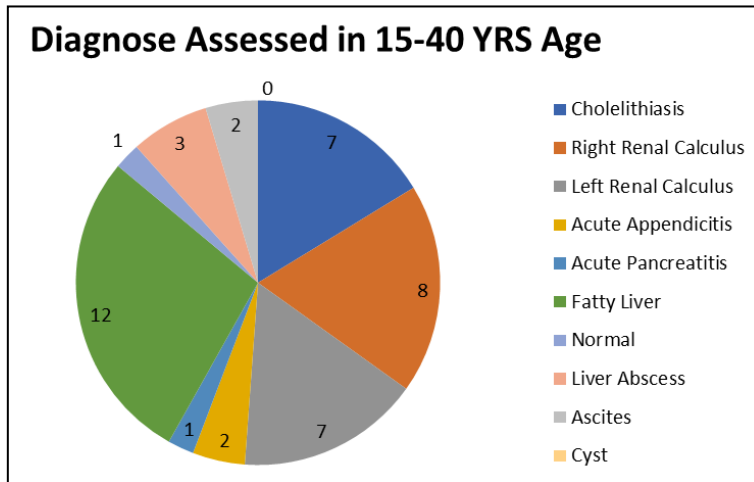
Overall	Result in percentage
Cholelithiasis	21.25%
Right Renal Calculus	13.75%
Left Renal Calculus	10%
Acute Appendicitis	3.75%
Acute Pancreatitis	5%
Fatty Liver	23.75%
Normal	1.25%
Liver Abscess	2.5%
Ascites	7.5%
Cyst	7.5%
B/L Renal Calculus	3.75%



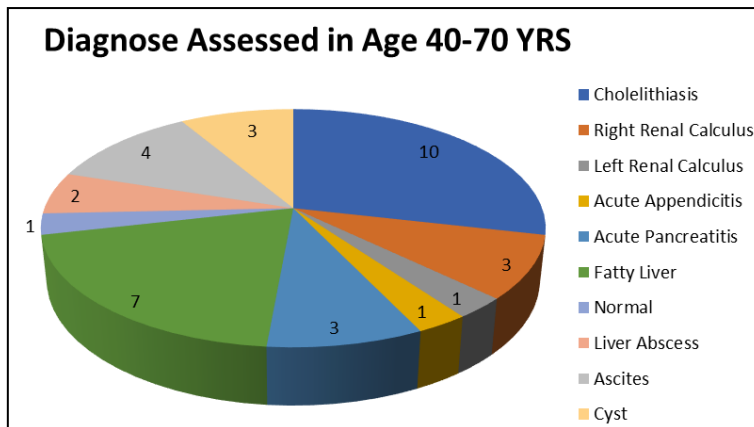
Graph 1: represents the percentage of male and female patients undergo USG abdomen having acute abdominal pain.



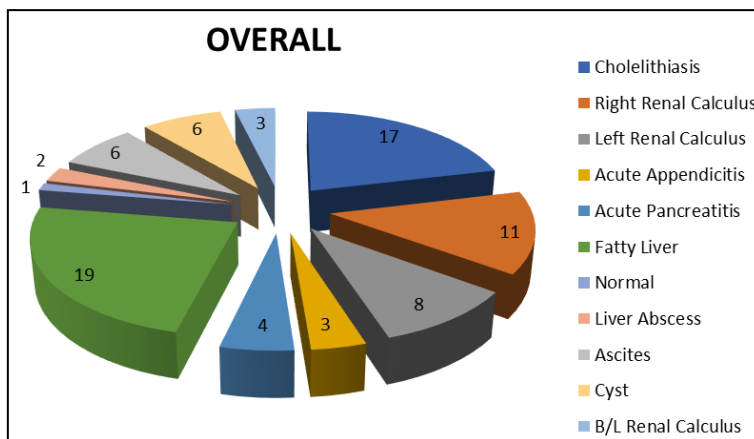
Graph 2: represents the total number of patients in each age group.



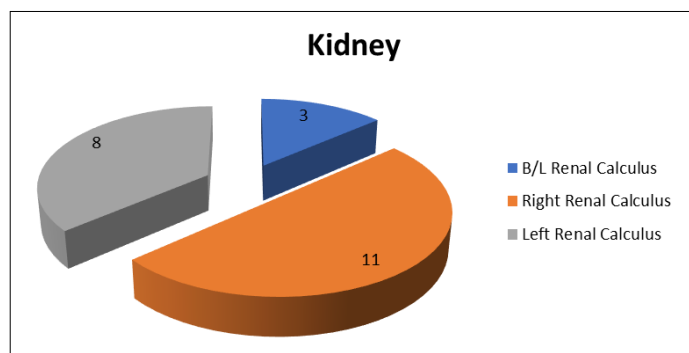
Graph 3: represents the no. of patients of different USG assessment results in age group 15-40 years.



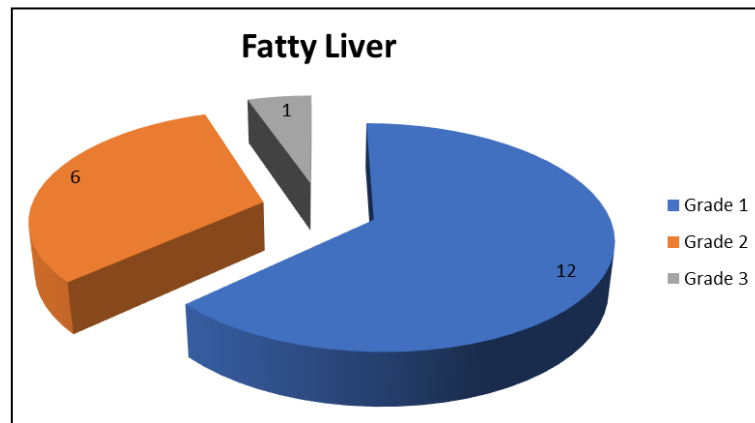
Graph 4: represents the no. of patients of different USG assessment results in age group 40- 70years.



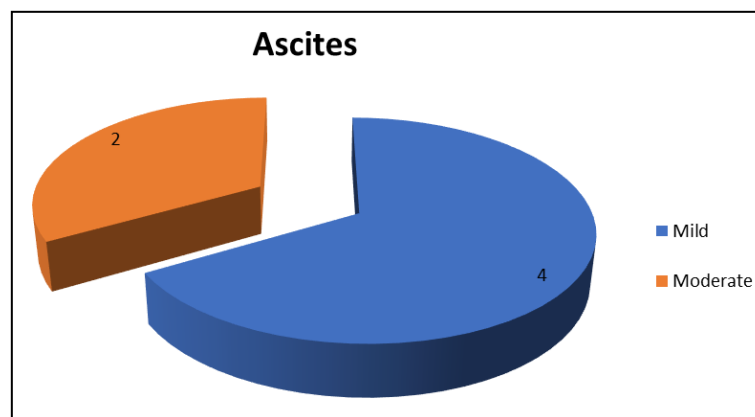
Graph 5: represents the total number of patients from overall sample for different usg assessment results.



Graph 6: represents the total number of patients from overall sample for different usg of kidneys



Graph 7: represents the total number of patients from overall sample for different USG of fatty liver



Graph 8: represents the total number of patients from overall sample for different USG of ascites

Discussion

In this study assessment of acute abdominal pain in ultrasonography was done. This study is inspired by a research conducted by M. Antonietta Mazzei *et al.* who performed a study on the role of US examination in the management of acute abdomen. Acute abdomen is a medical emergency, in which there is sudden and severe pain in the abdomen of recent onset with accompanying signs and symptoms that focus on abdominal involvement. It can represent a wide spectrum of conditions, ranging from benign and self-limiting disease to a surgical emergency. Nevertheless, only one-quarter of patients who have previously been classified with an acute abdomen actually receive surgical treatment [18]. An ultrasound test uses high-frequency sound waves to create images of the patient's internal organs. Imaging tests can identify abnormalities and help doctors diagnose conditions. An abdomen ultrasound is a type of ultrasound used by doctors to examine abdominal organs. This includes the organ liver, pancreas, gallbladder, kidneys, intestines, etc. in this study most common Diagnose is finding out in the male patients taken as samples of age group between 15 to 70 years. And Fatty liver was the most common finding after the calculation of results. This may need clinical as well as surgical treatment to be done. This study performed here because no study was done before on the topic of acute abdomen pain assessment.

Conclusion

It is concluded that ultrasound is the best modality to rule out the problems at an earlier stage so that treatment can be started on behalf of reports of Ultrasonography scan in patients of acute abdominal pain, as it is fast and safe to patients, it does not include any ionizing radiation so female patients of reproductive age go through scan without any risk. The study concludes uses of USG should be performing as a primary investigation for all patients. This study has shown a relatively high sensitivity, specificity and diagnostic accuracy of USG in cases of acute abdomen in a careful hand. USG is currently considered the preferred initial imaging technique for patients who are clinically suspected of having fatty liver, renal calculus, acute pancreatitis, acute appendicitis, ascites, cyst, liver abscess and Cholelithiasis etc. And the most common reason for acute abdominal pain as per this study is Fatty liver, 23.75% of patients having Fatty liver when USG was performed. 1.25% of patients have a normal scan with no findings. In rest 98.75% patient's ultrasound help to diagnose the problem of acute pain.

Contributors

All authors contributed to the conception or design of the work, the acquisition, analysis, or interpretation of the data. All authors were involved in drafting and commenting on the paper and have approved the final version.

Funding

This study did not receive any specific grant from funding agencies in the public, commercial, or not-for-profit sectors.

Conflict of Interest

The author has no conflict of interest.

Disclosure

The author did not receive any type of commercial support in forms of either compensation or financial support for this study.

Ethical approval & Informed consent was obtained from all participants.

References

1. Madeleine J Marsland, Dunya Tomic, Pamela L Brian, and Michelle D Lazarus. Abdominal Anatomy Tutorial Using a Medical Imaging Platform doi: 10.15766/mep_2374-8265.10748
2. Lakshay Chanana, Moses AK Jegaraj, Kimmin Kalyaniwala, Bijesh Yadav, and Kundavaram Abilash Clinical profile of non-traumatic acute abdominal pain presenting to an adult emergency department doi: 10.4103/2249-4863.161344
3. Gianfranco Cervellin, Riccardo Mora, Andrea Ticinesi, Tiziana Meschi, Ivan Comelli, Fausto Catena, *et al.* Epidemiology and outcomes of acute abdominal pain in a large urban Emergency Department: retrospective analysis of 5,340 cases doi: 10.21037/atm.2016.09.10
4. John W. Patterson, Sarang Kashyap, Elvita Dominique. Bookshelf ID: NBK459328 PMID: 29083722
5. Christopher R Macaluso and Robert M McNamara Evaluation and management of acute abdominal pain in the emergency department doi: 10.2147/IJGM.S25936
6. Mojtaba Fazel, Mohammed I M Gubari, Mahmoud Yousefifard, and Mostafa Hosseini. Ultrasonography in Detection of Renal Calculi in Children; a Systematic Review and Meta-analysis PMID: PMC6942918
7. Singal Rikki, Mittal Amit, Gupta Samita, Singh Bir, and Jain Parul, Management of gall bladder perforation evaluation on Ultrasonography PMID: PMC3227160
8. Georg Dimcevski, Friedemann G Erchinger, Roald Havre, and Odd Helge Gilja Ultrasonography in diagnosing chronic pancreatitis: New aspects doi: 10.3748/wjg.v19.i42.7247
9. Tristan Reddan Jonathan Corness Kerrie Mengersen Fiona Harden Ultrasound of paediatric appendicitis and its secondary sonographic signs: providing a more meaningful finding doi: 10.1002/jmrs.154
10. Ali Abdolrazaghnejad1, Ali Rajabpour-Sanati2, Hojjat Rastegari-Najafabadi1, Maryam Ziaei1, Abdolghader Pakniyat3*. The Role of Ultrasonography in Patients Referring to the Emergency Department with Acute Abdominal Pain DOI:10.22114/ajem.v0i0.152
11. Minoru Tomizawa, Fuminobu Shinozaki, Rumiko Hasegawa, Yoshinori Shirai, Yasufumi Motoyoshi, Takao Sugiyama, *et al.* Abdominal ultrasonography for patients with abdominal pain as a firstline diagnostic imaging modality
12. Niranjan Sahu, Sibanarayan Rath, Rabindra N. Padhy. Role of Abdominal Ultrasound in the Diagnose of Typhoid Fever in Pediatric Patients doi.org/10.1016/j.jmu.2016.09.002
13. Charu Tiwari, Gursev Sandlas, Shalika Jayaswal, Hemanshi Shah. Outcome analysis of acute abdominal pain and correlation of Alvarado score with Diagnose DOI: 10.4103/2320-3846.175213
14. Prasad, Hari and Rodrigues. Gabriel and Shenoy Role Of ultrasonography in non-traumatic acute abdomen <http://eprints.manipal.edu/id/eprint/142824>Christian I. Wade; Matthew J. Streitz. Anatomy, Abdomen PMID: 31971744
15. Andrews MA1, Patel NB2, Jadav J3, Patel NJ4, Leuva HL5, Shah. RC6 Role of abdominal Ultrasonography in Diagnose of acute abdomen doi:10.17511/ijmrr.2015.i3.059.
16. Peiman Nazerian, Camilla Tozzetti, Simone Vanni, Maurizio Bartolucci, Simona Gualtieri, Federica Trausi, *et al.* Accuracy of abdominal ultrasound for the Diagnose of pneumoperitoneum in patients with acute abdominal pain: a pilot study doi: 10.1186/s13089-015-0032-6
17. Bal Kishan Gupta, Hardeva Ram Nehara, Sahil Parmar, Shyam Lal Meena, Suresh Gajraj Jigyasa Gupta Acute abdomen presentation in dengue fever during recent outbreak doi:10.4103/2221-6189.219612
18. Maria Antonietta Mazzei 1, Susanna Guerrini1, Nevada Cioffi Squitieri1, Lucio Cagini2, LucaMacarini3, Francesco Coppolino4, *et al.* Show fewer authors The role of US examination in the management of acute abdomen
19. Russo A, Cappabianca S, Francesco Iaselli, Reginelli A, D'Andrea A, Mazzei G, *et al.* Acute abdominal pain in childhood and adolescence: assessing the impact of sonography on Diagnose and treatment doi: 10.1007/s40477-013-0040-y
20. Scammell S, Lansdale N, Sprigg A, Campbell D, and Marven S. Ultrasonography aids decision-making in children with abdominal pain doi:10.1308/003588411X582672.