



---

## USG correlation with X-Ray for the evaluation of pleural effusion with quantitative analysis

Anchal Saini<sup>1</sup>, Kajal Tyagi<sup>3</sup>, Khusbu Yadav<sup>2</sup>, Anshu Kumar Singh<sup>3</sup>

<sup>1</sup> Scholar, SGT University, Gurugram, Haryana, India

<sup>2</sup> Radio Technologist, Birat Medical College and Teaching Hospital, Nepal

<sup>3</sup> Assistant Professor, Department of Paramedical Sciences, Swami Vivekanand Subharti University, Meerut, Uttar Pradesh, India

---

### Abstract

The present study "USG correlation with X-ray for evaluation of pleural effusion with quantitative analysis" is a prospective study conducted in patients to find the correlation of USG and X-Ray in evaluation of pleural effusion in radio-diagnoses and imaging in SGT, University hospital. The study was done in 20 patients of all age and sex without discriminating in age and sex. The study had 7 females (35%) and 13(65%) where male of average age 38.3 years is included. Breathlessness was most common cause accounting 16(80%) out of 20 patient 10(50%) male and 3(15%) female had pleural effusion in Right lung and 5(25%) female and 6(30%) males had pleural effusion in left lung average volume of effusion in male 36.49ml left lung and 118.97 ml in left lung female USG diagnosed with more effectiveness 3 case of left lung and 4 right lung pleural effusion had negative results on X-ray but not on USG.

**Keywords:** USG, ultrasonography, pleural effusion, pleural cavity, inflammation

---

### Introduction

Pleural effusion is the strange accumulation of fluid in pleural hollow space attributable to inflammation. Generally small amount of fluid (few ml) is gift within the pleural cavity which enables in everyday functioning of lungs all through respiratory.

### Anatomy of Pleural Space

In every lung there are pleura which protect the body of the lung. It is miles made of a layer of simple squamous cellular that supported through the connective tissue <sup>[1]</sup>.

### Visceral pleura

It lined the outer surface of lungs.

### Parietal pleura

It is the inner layer of lungs.

The gap which separate visceral pleura from parietal pleura is referred to as visceral area. Which contain small of surfactant fluid? The space between these two layers is likewise referred to as pleural hollow space <sup>[2]</sup>.

### Pleural fluid formation

Pleural fluid secretes from pleural capillaries via micro- vasculature throughout the capillary endothelium and inters ilium <sup>[3]</sup>.

### Appearance of pleural fluid

A crimson patchy appearance of the pleural fluid restriction the differential diagnosis, high viscosity of pleural fluid may be due to mobile particles, excessive lipid degree and the order of pleural fluid

### Types of pleural Effusions

Pleural Effusion can be in addition divided into 2 types: - Exudate and Transudates depending on the biochemical analysis of aspirated Pleural Fluid.

### Cause of pleural Effusions

A transudate pleural effusion as a result of imbalanced hydrostatic or oncotic strain. He most common causes are: coronary heart failure, cease stage kidney sickness, peritoneal dialysis and myxoedema. An exudate pleural effusion occurs when there may be an inflammation which purpose endothelium to grow to be leakier

and allow free passage of lymphatic fluid. The most commonplace reasons are: bacterial pneumonia, viral contamination, pulmonary embolism and T.B <sup>[4]</sup>.

### **Symptoms of pleural effusion includes**

Shortness of breath, chest pain particularly whilst breathing deeply i.e., pleuritic pain, fever, cough. If Pleural area includes both Air and Fluid Then Air Fluid stage that is horizontal might be present as opposed to Confirming to The Lung area.

### **Radiographic Feature for Diagnosis of Pleural Effusion by Xray.**

#### **Plain Radiograph**

The most frequent method of assessing pleural effusion is to take a chest radiograph. Before it becomes visible, at least 250 mL to 600 mL of liquids must be present

#### **Lateral Decubitus**

It is the Most Sensitive, Detecting a Tiny Amount of Fluid. It is obtained via a cross table shoot through technique with the patient lying on their side, effusion side down.

#### **Erect Projection**

Small quantities of fluid have no effect on PA and AP Erect Film. Blunting of the Costophrenic Angle and Cardiophrenic Angle, fluid inside horizontal or oblique fissures are some of the characteristics.

#### **Supine Position**

Because fluid is reliant and accumulates posteriorly, a chest radiograph taken in the supine position can detect a large amount of fluid with few imaging changes. Because a veil-like increased density of the hemithorax may be seen, identifying similar-sized bilateral effusion is difficult because the densities of the lungs will be similar.

USG can detect a little quantity of fluid (3-5 ml) that would be missed by a radiograph. Radiography's sensitivity is defined as the ability to detect a minimum of 50 mL of fluid. The USG examination of a patient in a sitting posture is preferable because it allows for more exact pleural effusion quantification. The free fluid is collected in the dependent space in this position, whereas it is located in a posterior region with the patient in a supine position. The difference between Loculated pleural fluid and Thickened pleura may be easily distinguished using ultrasound. It enables for the recognition of nearby structures such as the chest wall, hemidiaphragm, and visceral pleural surface. Pleural fluid is generally hypo echoic (darker) when compared to the isochoric reference of the liver and spleen, while air-filled lung is hyper echoic (brighter). Ultrasound is clearly more sensitive than a lateral Decubitus chest radiograph for detecting pleural effusions, and when compared to chest X-ray, Ultrasound of the chest has been reported to have "95 percent sensitivity for detecting pleural lesions in Patients with a white out" on chest Radiography. Loculated Pleural Fluid and Thickened Pleura are easily distinguished using ultrasound. Even with little fluid collections, it is effective in guiding thoracentesis <sup>[5]</sup>.

#### **Justification**

This study carried out because of the large number of patients for chest X-ray Examination had come here in our radiology department and among them most of the patients were commonly diagnosed for the pleural effusion and for this reason we compared this Examination with Ultrasonography so that this study will be beneficial for our further study or in the future as well. This May Lead to Variation in Dose Radiation Patient Receives. Hence, The Study Will Allow to Achieve the Proper Classification and help Us Uphold Ethical Values of Patient Welfare by Evaluating Pleural Effusion with Quantitative Analysis and Using Techniques That Are the Best to Increase Quality of Images.

#### **AIM**

USG correlation with x-ray for the evaluation of pleural effusion with quantitative analysis

#### **Objectives**

- To study the correlation of ultrasound with X-Ray for determining the amount of aspirated effusion and evaluate pleural effusion.
- To compare between the Ultrasound and X-Ray for analysis of pleural fluid.

#### **Material and Methods**

The research process begins with the design and methodology of the study. These should be chosen with care since they have a significant impact on the effectiveness of a research endeavour. Pleural effusion can be defined as accumulation of unwanted fluid in between the tissues in the lungs and chest which hinder the normal functioning of the lungs <sup>[22]</sup>.

In current study, a quantitative analysis is done between the X Ray and Ultrasound to find out better modality for evaluating the quantity of pleural effusion. The study was conducted in department of Radio diagnosis of SGT Hospital for a period of 6 month.

**Study Type**

Prospective, Observational, and comparative study.

**Study Duration**

The duration of the study is period of 6 months.

**Study Area**

The source of data for this study includes total 20 patients referred to department of Radio- Diagnosis Imaging for chest radiography and ultrasonography from OPD/IPD/ED of SGT Hospital, Gurugram. Among which 13(65%) were male and 7(35%) were female of average age 38.3years.

**Inclusion Criteria**

- All the Patient with post-diagnosed of pleural effusion, All the patient IPD & OPD, Both male & female patient were included, No age limitation

**Exclusion Criteria**

- Pregnancy, Those patients who were not diagnosed with pleural effusion

**Methodology**

- All the patients who have come for Chest Imaging.
- After the X Ray of Chest is done, if case of any doubt of Pleural effusion, the USG Chest is performed and vice versa.

**Result**

In this prospective study 20 patients were included, out of which 13(65%) were male and 7 (35%) were female, the average age of patient were 38.3 years. In this study we included only those patients who undergo for both scan x-ray as well as USG for identify the pleural effusion. Results from USG showed 10(50%) male and 3(15%) females had pleural effusion in right lung whereas 5(25%) female and 6(30%) males had pleural effusion in left lung.

In x-ray images 8(40%) males and 2(10%) females showed pleural effusion in right lung and 4(20%) female, 3(15%) males had effusion in their left lung. 3(15%) patients had effusion in their right lungs in USG images but not on their X-ray results, while 4(20%) patients' USG images showed effusion in left lung which cannot be seen on their X-rays. For right lung minimum volume of fluid level 37.8ml and 346mL was maximum volume and the average volume was 93.98mL. In left lung minimum 37.8 ml of fluid was detected and maximum recorded was 221.4mL and average volume recorded is 60.1mL. Average volume of effusion in male was 36.49 in left lung and in right lung were 118.97. In female average effusion in right lung were 103.94 and in left was 63.31mL.the most common Symptoms among all patient were breathlessness out of 20 patient 16(80%) were suffered from breathlessness.

**Table 1:** Comparison pleural effusion between male and female

Male		Female	
Right Lung	Left Lung	Right Lung	Left Lung
45	0	0	37.8
103	63	0	185.6
0	43.2	0	206
344	0	208	0
104.6	221.4	0	188
165	0	189	0
0	57.8	46.2	110.2
346	0		
37.8	45		
0	44		
185	0		
106	0		
110.2	0		

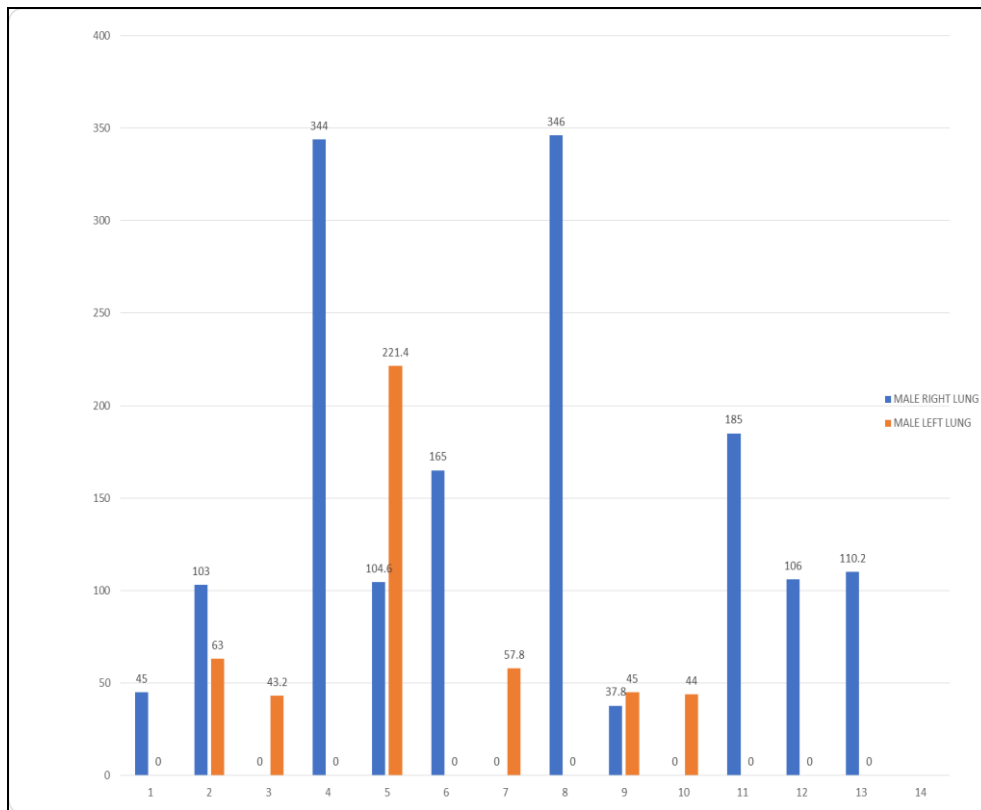


Fig 1

Table 2: Average of Pleural Effusion between male and female

Gender	Right Lung	Left Lung
male	118.97	36.49
female	63.31	103.94

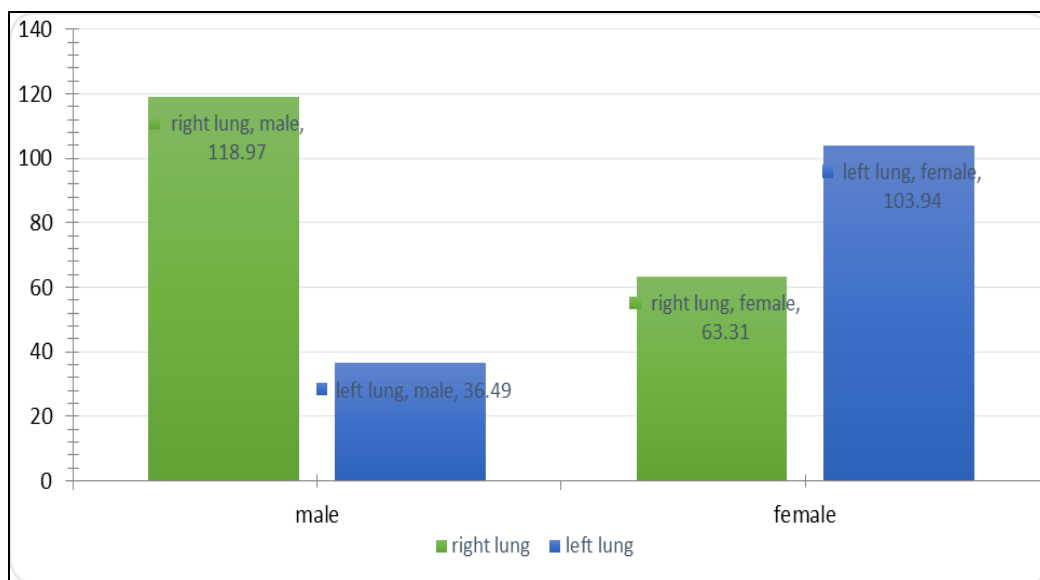


Fig 2: Average of Pleural Effusion between male and female

**Conclusion**

The present study "USG correlation with X-ray for evaluation of pleural effusion with quantitative analysis" is a prospective study conducted in patients to find the correlation of USG and X-Ray in evaluation of pleural effusion in radio-diagnoses and imaging in SGT, University hospital. The study was done in 20 patients of all age and sex without discriminating in age and sex. The study had 7 females (35%) and 13 (65%) where male of average age 38.3 years is included. Breathlessness was most common cause accounting 16(80%) out of 20 patient 10(50%) male and 3(15%) female had pleural effusion in Right lung and 5(25%) female and 6(30%) males had pleural effusion in left lung average volume of effusion in male 36.49ml left lung and 118.97 ml in

left lung female USG diagnosed with more effectiveness 3 case of left lung and 4 right lung pleural effusion had negative results on X-ray but not on USG. X-ray makes use of ionisation radiation which has severe dangers while USG is even in pregnant sufferers. USG is some distance superior than simple X-Ray in locating of minimal pleural & also for quantification of effusion pleural furthermore, intervention like pleural faucet can also done. USG can locate low amount of fluid presence even less than 3 ml, while X-ray fails to help diagnose such low quantity of fluid.

**Conflict of interest**

I declare that there is no conflict of interest.

**Author's Contributions**

All authors listed have made a substantial, direct, intellectual contribution to the work and approved it for publication.

**Funding**

None

**References**

1. Wang NS. Anatomy and physiology of the pleural space. *Clinics in chest medicine*, 1985;6(1):3-16.
2. Wang, Nai-San. "The preformed stomas connecting the pleural cavity and the lymphatics in the parietal pleura." *American Review of Respiratory Disease*, 1975;111(1):12-20.
3. Cheng DS, Rodriguez RM, Perkett EA, Rogers J, Bienvenu G, Lappalainen U *et al.* Vascular endothelial growth factor in pleural fluid. *Chest*, 1999;116(3):760-765.
4. D'Agostino HP, Edens MA. Physiology, Pleural Fluid. [Updated 2020 Sep 3]. In: Stat Pearls [Internet]. Treasure Island (FL): Stat Pearls Publishing, 2021.
5. McLoud TC, Flower CD. "Imaging the pleura: sonography, CT, and MR imaging." *AJR. American journal of roentgenology*, 1991;156(6):1145-1153.