



Role of computerized tomography (CT) in early prediction of stroke in subjects infected with Covid-19

Alaa EL-Din A A

Head of Radiology Departments, Kobri El-Kobba Military Medical Complex, Cairo, Egypt

Abstract

The central nervous system is a sensitive and vulnerable organ that is shielded by multiple layers of protective coverings. The Covid-19 infection may end with many chronic diseases as, respiratory distress, renal, cardio and neuro-disorders as stroke. The aim of current study used an advanced imaging as CT is important for early prediction and prevention of stroke in patients relived from Covid-19. Two hundred patients (100 males and 100 females) age range (35-55years) divided into 4 groups: Group I: Patients suffered from stroke with intracranial haemorrhage. Group II: Patients infected with Covid-19 and complete recovered. Group III: Patients suffered from stroke with previously Covid-19 infected. Group IV: Normal healthy subjects as control. Data obtained showed that, CT output showed sensitive and easy tool for detection of cerebral bleeding and severe early ischemic alterations compared with other groups. It is recommended for follow up the infected subjects by Covid -19 for early prediction of stroke by CT to avoid bad complications.

Keywords: computerized tomography, Covid-19, nervous system

Introduction

Computerized tomography (CT) scan is typically used for diagnosis cerebral haemorrhage or tumours, but they can also be utilised to detect early signs of an infarction. There was no change in density in ischemic tissue for the first two hours after stroke onset ^[1], but low incidence was found in patients scanned throughout the first six hours ^[2]. However, there is still a need for a stroke imaging technique that is quick and accurate. Stroke is a debilitating disease in which decrease blood supply to brain due to neurological blockage ^[3]. Radiological examinations are needed to important for diagnosis the location, magnitude and type of stroke. Current guidelines for treating acute stroke with intravenous (IV) thrombolysis with recombinant tissue-type plasminogen activator ^[4] are based on numerous major trials showing that this treatment is effective within the 3- or 4.5-hour time window ^[5].

The main drawback has been the decreasing efficacy of IV thrombolytic therapy once the time limit has passed. In these trials, however, the diagnosis of acute stroke was determined clinically with an additional non-enhanced computer tomography (NECT) examination to rule out cerebral bleeding and severe early ischemic alterations, both of which are regarded contraindications to thrombolytic therapy ^[6]. In most cases, however, in some parts of Africa, radiological testing like as CT scans aren't available since they're too expensive or prohibitively expensive, implying that the great majority a diagnosis of stroke. As a result, there is a need to examine these approaches on a regular basis in order to enhance the outcome of stroke cases. The Covid-19 was first described as an unusual pneumonia case in China. However it was reported to affect many body systems as well, liver, kidney, heart and neurological system ^[7]. Stroke is considered as one of diseases that increased morbidity and mortality ^[8]. Covid-19-related haemorrhagic stroke are significantly less prevalent than their ischemic counterparts ^[9].

While the exact cause of Covid-19-related haemorrhagic strokes is unknown, hyper-coagulable states, vacuities, and cardiomyopathy have all been implicated. It was reported that the viral affinity for the angiotensin converting enzyme -2 receptor found in the cerebral artery wall. ^[10]. Subjects with Covid -19-related stroke had a higher D-dimer level, lower haemoglobin levels and platelets count ^[11]. The stroke may be due to the pandemic nature of Covid-19 propagation and the proposed pathogenic mechanism of stroke in its patients. However, neurologists from around the world have reported a significant decrease in the number of acute stroke patients presenting to emergency rooms in recent months ^[12]. The aim of current study is to investigate the role of CT in early prediction of stroke in patients previously infected and recovered from Covid-19.

Subjects and Methods

This study was carried out according to the ethical committee of Armed Forces Hospitals. Informed consent was taken from all patients shared in this study. Two hundred patients (100 males and 100 females) age range (35-55years) divided into 4 groups: Group I: Patients suffered from stroke with intramural haemorrhage. Group II: Patients infected with Covid-19 and complete recovered. Group III: Patients suffered from stroke with previously Covid-19 infected. Group IV: Normal healthy subjects as control. Complete blood picture, serum ferritin, D-dimer, chest X- ray, RT-PCR for Covid-19, oxygen saturation level below 90%. All of the data was carefully gathered from hospital records and was completely anonymised. Exclusion criteria, a history of contrast medium allergy or renal failure were both exclusion criteria for CTA. Before enrolling in the research, all patients had a non-contrast-enhanced CT scan to rule out intra-cerebral haemorrhage. On patient arrival, the neuroradiology's on duty was paged from the neurological

emergency department to avoid any delays in starting therapy owing to experimental CT and stroke MRI.

Computed tomography (CT) scan.

The software estimated and presented cerebral blood volume (CBV), cerebral blood flow (CBF), and mean transit time (MTT). A color-coded automatic CTP-viability map was included in the software bundle. The penumbra (tissue at risk) was identified by green colour and described as a region where MTT was prolonged by more than 50% when compared to the contralateral hemisphere^[12]. The neurologist worked to evaluate the imaging data for evaluation and make treatment decision.

Statistical analysis

Data analysis was done by using SPSS version 20. Regressions analysis was used to evaluate the data for significant changes in weekly admission rates before and during the Covid-19 period.

Results

Immunological analysis showed a negative PCR for mRNA-Covid-19 to insure relive form infection. The biochemical analysis of infected subjects showed that, serum ferritin, D-dimer, lymphocytes still elevated significantly compared with non-infected (967 Vs 140 uN for ferritin, 340 µg Vs 56 µg for D Dimer and 76% Vs 40% for lymphocyte). The CT (fig 1) scan showed normal and clear background without any changes in blood vessels in normal subjects. Patients with ischemic stroke showed intracranial haemorrhage and reduced blood flow in CT help in detection of ischemia since the non-absence of hemorrhage is not enough to make a diagnosis of stroke, presence of hemodynamically compromised tissue, underlying cause as vascular occlusion, carotid stenosis), reperfusion or demonstrating failure and or complications such as emboli or bleeding.

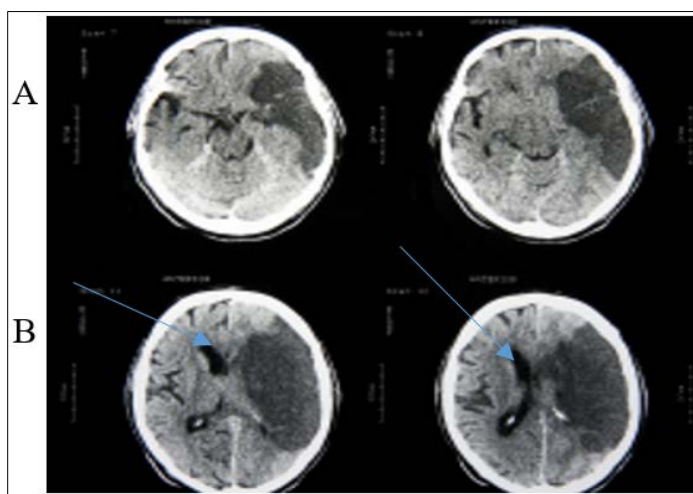


Fig 1: The CT image of normal subjects (A) and patients with infected with Covid-19 with intracranial haemorrhage.

Discussion

In diagnosis of patients with acute cerebral ischemia, computed tomography (CT) play an important role in early prediction for fast intervention. It is still easier to handling for hemorrhage detection since most radiologists are unfamiliar with magnetic

resonance (MR)^[13]. The challenge of most physicians have nowadays when dealing with radiography and this is especially true when dealing with an illness like stroke, is to offer a precise answer to a tough question fast utilizing a difficult technique. Because it is slightly faster than MR, and patient handling is easier, CT has stayed at the forefront of imaging in acute stroke. In current study we used CT scan for patients infected with Covid-19 to detect stroke and hemorrhage. It was found that, 20 out of 100 Covid-19 patients showed slightly bleeding as compared with normal. This cases recommended for follow up and prophylactic intervention for stroke. 10out of 100 suffered from hypertension showed stenosis in arteries. This is why it is the strategy that has been employed in major defining pharmacological trials for thrombolysis up to now, and it is the way that is recommended by most guidelines^[14]. While CT is the gold standard for excluding hemorrhage with certainty, the use of the other acute ischemia symptoms is a little more debatable. While the majority of patients have a poor prognosis^[15]. The presence or absence of bleeding, on the one hand, and the presence or absence of a substantial insular hypo density, on the other hand, are the truly established CT criteria for thrombolysis^[16]. Both of these signals have been shown to be useful in excluding people from therapy's potentially hazardous side effects. Patient with a left-hemispheric stroke who had intra-arterial thrombolysis. The CT scan indicates hyperdensity in the left basal ganglia, which corresponds to contrast thrombectomy^[17]. In the future, vascular recanalization therapies may make some of these findings less useful. Unfortunately, many scanners can detect a few slices. CT has considered the first choice for all acute stroke diagnosis^[18-21]. For complicated cases, the ischemic lesion related to ischemia or neuro-protective drugs, CT will not be as useful due to the less clear delineation of the acute lesions. CT itself is more advanced methods such as 320 row detector CT units^[22-26] or the advent of plat panel derived^[27]. CT will allow us to go faster, acquire more parameters and rendering acquisition, and evaluate more easily without slowing down the pre-therapeutic. The CT can detect any signs of massive infarction to help fast possible therapy. It was concluded that, CT served as sensitive, rapid and diagnostic tool for acute ischemic stroke, accurate diagnosis and early intervention for treatment.

References

1. Ringleb PA, Bousser MG, Ford G, et al. Guidelines for management of ischaemic stroke and transient ischaemic attack 2008. *Cerebrovascular Diseases*,2008;25(5):457–507.
2. Adams HP, Jr, Del Zoppo G, Alberts MJ, et al. Guidelines for the early management of adults with ischemic stroke: a guideline from the American heart association/American stroke association stroke council, clinical cardiology council, cardiovascular radiology and intervention council, and the atherosclerotic peripheral vascular disease and quality of care outcomes in research interdisciplinary working groups. *Stroke*,2007;38(5):1655–1711.
3. Marler JR. Tissue plasminogen activator for acute ischemic stroke. *New England Journal of Medicine*,1995;333(24):1581–1587.
4. Hacke W, Kaste M, Fieschi C, et al. Intravenous thrombolysis with recombinant tissue plasminogen activator

- for acute hemispheric stroke: the European Cooperative Acute Stroke Study (ECASS) Journal of the American Medical Association,1995;274(13):1017–1025.
5. Hacke W, Kaste M, Fieschi C, *et al.* Randomised double-blind placebo-controlled trial of thrombolytic therapy with intravenous alteplase in acute ischaemic stroke (ECASS II) *Lancet*,1998;352(9136):1245–1251.
 6. Clark WM, Wissman S, Albers GW, Jhamandas JH, Madden KP, Hamilton S. Recombinant tissue-type plasminogen activator (Alteplase) for ischemic stroke 3 to 5 hours after symptom onset the ATLANTIS study: a randomized controlled trial. *Journal of the American Medical Association*,1999;282(21):2019–2026.
 7. Hacke W, Donnan G, Fieschi C, *et al.* Association of outcome with early stroke treatment: pooled analysis of ATLANTIS, ECASS, and NINDS rt-PA stroke trials. *Lancet*,2004;363(9411):768–774.
 8. Hacke W, Kaste M, Bluhmki E, *et al.* Thrombolysis with alteplase 3 to 4.5 hours after acute ischemic stroke. *New England Journal of Medicine*,2008;359(13):1317–1329.
 9. Wahlgren N, Ahmed N, Dávalos A, *et al.* Thrombolysis with alteplase 3–4.5 h after acute ischaemic stroke (SITS-ISTR): an observational study. *The Lancet*,2008;372(9646):1303–1309.
 10. Brott T, Adams HP, Olinger CP, *et al.* Measurements of acute cerebral infarction: a clinical examination scale. *Stroke*,1989;20(7):864–870.
 11. Wintermark M, Maeder P, Thiran JP, Schnyder P, Meuli R. Quantitative assessment of regional cerebral blood flows by perfusion CT studies at low injection rates: a critical review of the underlying theoretical models. *European Radiology*, 2001;11(7):1220–1230.
 12. Wintermark M, Flanders AE, Velthuis B, *et al.* Perfusion-CT assessment of infarct core and penumbra: receiver operating characteristic curve analysis in 130 patients suspected of acute hemispheric stroke. *Stroke*. 2006;37(4):979–985.
 13. Nagel HD. Radiation Exposure in Computer Tomography. 4th edition. Hamburg, Germany: CTB; 2002.
 14. Lewandowski CA, Frankel M, Tomsick TA, *et al.* Combined intravenous and intra-arterial r-TPA versus intra-arterial therapy of acute ischemic stroke: emergency management of stroke (EMS) bridging trial. *Stroke*,1999;30(12):2598–2605.
 15. Broderick J. Combined intravenous and intra-arterial recanalization for acute ischemic stroke: the Interventional Management of Stroke Study. *Stroke*,2004;35(4):904–911.
 16. Broderick JP. The interventional management of stroke (IMS) II study. *Stroke*,2007;38(7):2127–2135.
 17. Rha JH, Saver JL. The impact of recanalization on ischemic stroke outcome: a meta-analysis. *Stroke*,2007;38(3):967–973.
 18. Del Zoppo GJ, Higashida RT, Furlan AJ, Pessin MS, Rowley HA, Gent M. PROACT: a phase II randomized trial of recombinant pro-urokinase by direct arterial delivery in acute middle cerebral artery stroke. *Stroke*,1998;29(1):4–11.
 19. Furlan A, Higashida R, Wechsler L, *et al.* Intra-arterial prourokinase for acute ischemic stroke. The PROACT II study: a randomized controlled trial. *Journal of the American Medical Association*,1999;282(21):2003–2011.
 20. Mullins ME, Schaefer PW, Sorensen AG, *et al.* CT and conventional and diffusion-weighted MR imaging in acute stroke: study in 691 patients at presentation to the emergency department. *Radiology*,2002;224(2):353–360.
 21. Launes J, Ketonen L (1987) Dense middle cerebral artery sign: an indicator of poor outcome in middle cerebral artery area infarction. *J Neurol Neurosurg Psychiatry*,50(11):1550–1552.
 22. Grotta JC, Welch KM, Fagan SC, Lu M, Frankel MR, Brott T *et al.* Clinical deterioration following improvement in the NINDS rt-PA Stroke Trial. *Stroke*,2001;32(3):661–668
 23. Manno EM, Nichols DA, Fulgham JR, Wijdicks EF. Computed tomographic determinants of neurologic deterioration in patients with large middle cerebral artery infarctions. *Mayo Clin Proc*,2003;78(2):156–160.
 24. Leary MC, Kidwell CS, Villablanca JP, Starkman S, Jahan R, Duckwiler GR, *et al.* Validation of computed tomographic middle cerebral artery “dot” sign: an angiographic correlation study. *Stroke*,2003;34(11):2636–2640
 25. Barber PA, Demchuk AM, Hudon ME, Pexman JH, Hill MD, Buchan AM. Hyperdense sylvian fissure MCA “dot” sign: a CT marker of acute ischemia. *Stroke*,2001;32(1):84–88
 26. Na DG, Kim EY, Ryoo JW, Lee KH, Roh HG, Kim SS, *et al.* CT sign of brain swelling without concomitant parenchymal hypoattenuation: comparison with diffusion- and perfusion-weighted MR imaging. *Radiology*,2005;235(3):992–998
 27. Dzialowski I, Weber J, Doerfler A, Forsting M, von Kummer R. Brain tissue water uptake after middle cerebral artery occlusion assessed with CT. *J Neuroimaging*, 2004;14(1):42–48