



---

## Postpartum ovarian vein thrombosis: A case report

Christian Tomboravo<sup>1</sup>, Lova Hasina Rajaonarison NY Ony Narindra<sup>2</sup>, Alice Patrice Razafindrahova<sup>3</sup>, Ahmad Ahmad<sup>4</sup>

<sup>1-4</sup> Medical Imaging Department of Joseph Ravoahangy Andrianavalona Hospital, University of Antananarivo, Madagascar

---

### Abstract

Ovarian vein thrombosis (OVT) is a rare, potentially severe complication of the postpartum. Its diagnosis is often difficult due to its misleading clinical presentation. We report the observation of a 38-year-old patient who presented a right iliac fossa pain with fever at ninth day of cesarean section. The diagnosis of OVT was established by the abdominopelvic CT scan. The patient was treated with antibiotic and anticoagulant with an improvement of her state.

**Keywords:** thrombosis, ovarian vein, postpartum

---

### 1. Introduction

Ovarian vein thrombosis (OVT) is a rare postpartum complication [1]. This is a serious condition due to its possibility of extension to inferior vena cava and because of the risk of pulmonary embolism, whence the importance of a rapid diagnosis to initiate treatment [2]. We report a case of post-cesarean right ovarian vein thrombosis revealed by febrile pelvic pain in order to describe its clinical and radiological characteristics.

### 2. Observation

It was a 38 year old female (gravida 2, para 2), who had a caesarean section for a breech presentation. On the ninth postoperative day, she felt right lower quadrant pain associated with a temperature of 38.5 ° C. Clinical examination showed a soft abdomen, a tenderness in right lower quadrant, without any palpable mass. The surgical incision was clean, so was the lochia, and the vaginal touch revealed a tenderness on the right side during uterine mobilization. The laboratory exam showed a high white blood cell count 13 100 / mm<sup>3</sup> and CRP level of 108 mg / ml. Urine and vaginal samples for cytobacteriological examination were without abnormalities. Because of bowel gas, the abdominal and pelvic ultrasound was inconclusive. CT scan of the abdomen and pelvis allowed to diagnose a right ovarian vein thrombosis by showing a thick tubular structure with hypodense center, from the right latero-uterine region, extending along the right psoas muscle anterior face reaching the right renal pedicle (Figure 1a and 1b). The patient was transferred to the intensive care unit of Gynecology and Obstetrics Department for continuous hemodynamic monitoring, due to the high risk of pulmonary embolism. Anticoagulation was started with Enoxaparin 1 mg / kg twice a day and intravenous antibiotic composed of cefotaxime and metronidazole was prescribed. The clinical and biological infectious syndrome regressed after two days of treatment. The patient was discharged home ten days later with oral antivitamin K (Sintrom®), 3/4 tablet a day for six

months. Contraceptive implant (Implanon ®) was inserted before discharge. A coagulation test revealed no abnormalities. An abdominopelvic CT scan at six months of treatment showed a complete resolution of the thrombus of the right ovarian vein.

### 3. Discussion

Postpartum OVT of is a rare complication which can threatening mother's life. Thrombosis extension to the inferior vena cava leads risk of pulmonary embolism and requires urgent management [3].

Austin reported a case of OVT for the first time in 1956 [4]. It is a rare complication that occurs preferentially during the first two weeks of postpartum, with an incidence of 0.05 to 0.18% deliveries [3]. According to Lerouge *et al* [3], its incidence after caesarean section was 0.42% and would be more likely in multipara with an average parity of 2.4 and a mean age of 30 years. Its pathophysiological mechanisms are unclear. Nevertheless, like all phlebitis, Virchow's triad would be the origin of this complication [2]. It combines 3 factors:

- A hypercoagulability state linked to increased production of some procoagulant factors inherent to pregnancy and which continues until the 6 weeks of postpartum with a peak on the 4th day [5].
- Venous stasis resulting from ovarian vein dilation during pregnancy associated with a slowing of blood flow that occurs in the immediate postpartum [3].
- Alteration of the venous wall that may result from direct trauma caused by caesarean section [6].

Seventy to 90% of cases affect right ovarian vein. Both left and right ovarian vein are involved in 14 to 20% of cases, and it concerns the left ovarian vein only in 6 to 12% of cases [2]. Predominance of right involvement would be explained by the compression of the right ovarian vein due to dextrorotation of a large uterus and by the existence of antegrade flow of blood in the right ovarian vein while it is retrograde in the left ovarian vein

[2].

OVT has misleading and nonspecific presentation. Symptoms most often begin in the first week after delivery. It is an abdominal pain syndrome located in the iliac fossa or in the lumbar fossa, febrile, which can mimic pyelonephritis, acute appendicitis, or pelvic affection (ovarian torsion, tubo-ovarian abscess, endometritis, broad ligament hematoma) [2].

The standard laboratory exam generally reveals a non-specific biological inflammatory syndrome characterized by neutrophil leukocytosis and elevation of CRP [3].

Sectional imaging allows a definitive diagnosis and eliminate the need for exploratory surgery. On ultrasound, OVT is seen as a large echoic tubular structure, roughly cylindrical, localized in the retroperitoneal space, in latero-cava or latero-aortic seat, in front of the psoas muscle. Extension to the inferior vena cava can be visualized. On color-Doppler US, there is no color-flow filling the vessel [2]. Sensitivity of abdominal ultrasound for the diagnosis of postpartum OVT is 50%, because of digestive interposition [3].

All authors agree on the superiority of CT compared to other imaging techniques to assert the positive diagnosis of ovarian vein thrombosis. Recent thrombosis is seen as an enlarged vein with spontaneous intraluminal hyperdensity [2]. CT with injection of contrast media shows peripheral enhancement. CT signs of old thrombus associate an intraluminal hypodensity with an annular enhancement related to the opacification of "vasa-vasorum". The thrombus head can be spontaneously hyperdense with an

inferior older part which is hypodense. The presence of a gas hypodensity inside the thrombus means its septic character [7].

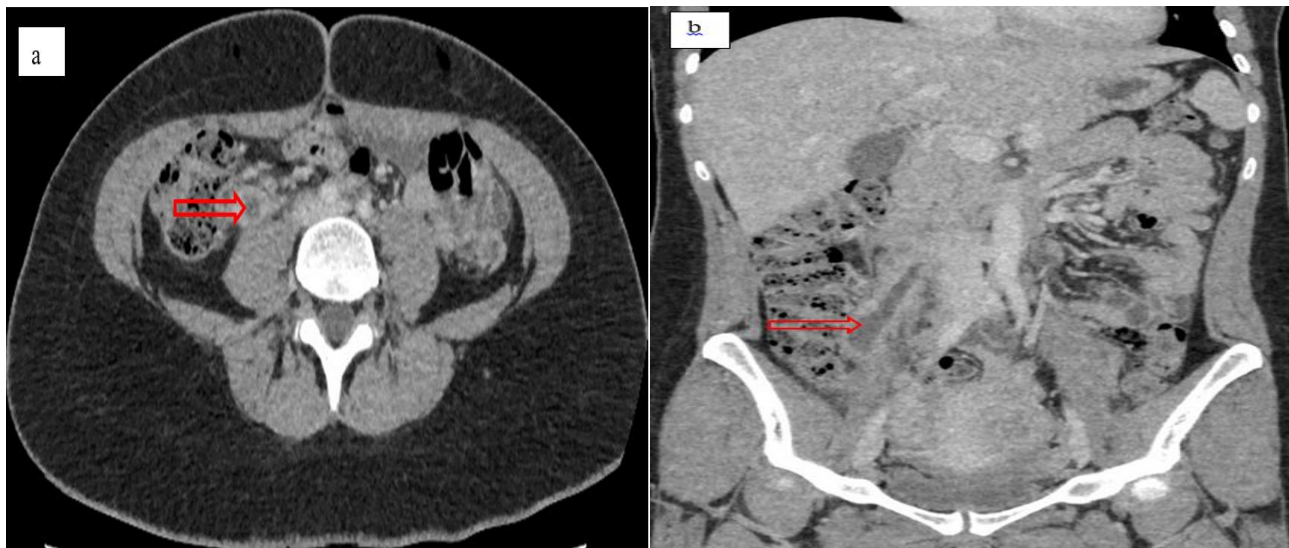
On MRI, the thrombus appears as an intermediate signal on T1 weighted image and the thrombosed vein is like a cockade on T2 weighted image (a central hypointensity, a hyperintense edging related to methemoglobin and a hypointense peripheral zone related to hemosiderin) [3].

Beyond the positive diagnosis, imaging will allow to characterize the thrombus: its age, its extension as well as its floating character or not [3].

Thrombosis of the ovarian vein can be life-threatening through septic shock or thrombosis extension, particularly to the renal veins, the inferior vena cava, and pulmonary arteries causing the much-feared pulmonary embolism. Nevertheless, thanks to imaging techniques, the diagnosis is made earlier and the evolution is generally favorable under treatment [3, 7].

Treatment is mostly medical and based on a broad-spectrum antibiotic therapy that covers anaerobic and Gram-negative bacilli associated with anticoagulant: a curative dose of heparin relay by antivitamin K for six months with good efficiency [3, 8]. Surgery is indicated when anticoagulants are contraindicated, or when medical treatment failed. The procedure consists of a ligation of the concerned vein. Floating thrombus in the inferior vena cava is an indication of setting up a temporary cava filter [3, 7].

#### 4. Figures



**Fig 1:** Abdominal CT scan image after injection of contrast media in axial section (a) and coronal section (b), showing thrombosis of the right ovarian vein (red arrow)

#### 5. Conclusion

Thrombosis of the ovarian vein is a rare condition. His clinical presentation is often misleading and can delay diagnosis and treatment. However, any postpartum fever associated or not with pelvic pain must be reminiscent of this diagnosis, especially if it resists well-conducted antibiotic therapy.

#### 6. References

1. Naoum J, Mohsen A, Daher J, Eid T. Novel management of ovarian vein thrombosis: A case report. Saudi

Pharmaceutical Journal. 2018; 26:608-610.

2. Slim K, Chaouki M, Sana M. Postpartum ovarian vein thrombosis: An unrecognized emergency. *mt Médecine de la Reproduction, Gynécologie Endocrinologie*. 2011; 13(2): 119-123.
3. Lerouge J, Sanguin S, Gondry J, Sergent F. Management of postpartum ovarian vein thrombosis. The experience of Amiens university hospital; *Gynécologie Obstétrique & Fertilité*. 2016; 44:88-95.
4. Austin OG. Massive thrombophlebitis of the ovarian veins;

- a case report. Am J ObstetGynecol. 1956; 72 (2):428-429.
5. Kuehnl A, Assadian A, Reeps C, Maria Schneider KT, Stangl M, Berger H. *et al.* Thrombus cave flottant à partir de la veine ovarienne. Ann ChirVasc. 2009; 23(5):747.e13-1.
  6. Quarello E, Desbriere R, Hartung O, Portier F, d'Ercole C, Boubli L. *et al* Postpartum ovarian vein thrombophlebitis: report of 5 cases and review of the literature. J Gynecol Obstet Biol Reprod. 2004; 33(5):430-440.
  7. Hafsa C, Golli M, Jerbi-Omezzine S, Salem R, Kriaa S, Zbidi M. *et al.* A rare aetiology of the post-partum fever: ovarian vein thrombophlebitis. Annales Franc, aises d'Anesthésie et de Réanimation. 2006; 25:286-290.
  8. Abdeljalil K, Sahbi K, Regaya LB, Anouar C, Habib S, Monia N. *et al.* Thrombophlébite de la veine ovarienne : une urgence à ne pas méconnaître. Imagerie de la Femme. 2010; 20:165-168.